



Owner's Copy

PennHIP Report

Referring Veterinarian: Dr Phyllis Frost	Clinic Name: Avenue of the Saints Animal Hospital
Email: info@avesaints.com	Clinic Address: 2221 4th Street SW Waverly, IA 50677
	Phone:
	Fax:

Patient Information

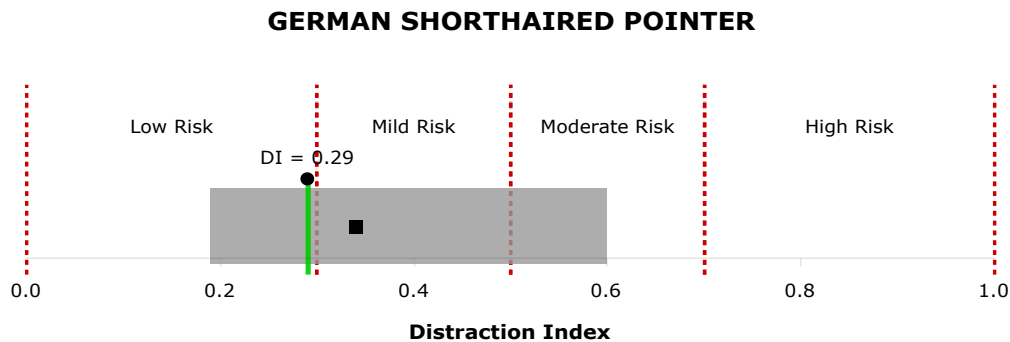
Client: Swieter, Robbie	Tattoo Num:
Patient Name: Ida	Patient ID: 17529
Reg. Name: Ida Da Pheasant Finda	Registration Num: SS30107806
PennHIP Num: 194424	Microchip Num: 985141003977433
Species: Canine	Breed: GERMAN SHORTHAIRED POINTER
Date of Birth: 28 Sep 2021	Age: 25 months
Sex: Female	Weight: 53.2 lbs/24.1 kgs
Date of Study: 04 Oct 2023	Date Submitted: 04 Oct 2023
Date of Report: 05 Oct 2023	

Findings

Distraction Index (DI): Right DI = 0.29, Left DI = 0.22.
 Osteoarthritis (OA): **No radiographic evidence of OA for either hip.**
 Cavitation/Other Findings: No cavitation present.

Interpretation

Distraction Index (DI): The laxity ranking is based on the hip with the greater laxity (larger DI). In this case the DI used is 0.29.
 OA Risk Category: The DI is less than or equal to 0.30. This patient is at minimal risk for hip OA.
 Distraction Index Chart:



BREED STATISTICS: This interpretation is based on a cross-section of 1720 canine patients of the GERMAN SHORTHAIRED POINTER breed in the AIS PennHIP database. The gray strip represents the central 90% range of DIs (0.19 - 0.60) for the breed. The breed average DI is 0.34 (solid square). The patient DI is the solid circle (0.29).

SUMMARY: The degree of laxity (DI = 0.29) falls within the central 90% range of DIs for the breed. This amount of hip laxity places hip at a minimal risk to develop hip OA. **No radiographic evidence of OA for either hip.**